

# A Structured, Tagged, and Localized Visual Question Answering Dataset with Full Sentence Answers and Scene Graphs for Chest X-ray Images

Philip Müller<sup>1</sup>, Friederike Jungmann<sup>1</sup>, Georgios Kaissis<sup>2</sup>, and Daniel Rueckert<sup>1,3,4</sup>

[philip.j.mueller@tum.de](mailto:philip.j.mueller@tum.de)

<sup>1</sup> Technical University of Munich (TUM) and TUM University Hospital, Germany

<sup>2</sup> Hasso Plattner Institute for Digital Engineering, University of Potsdam, Germany

<sup>3</sup> Imperial College London, UK

<sup>4</sup> Munich Center for Machine Learning (MCML), Germany

# Our QBA Dataset

**A large-scale VQA dataset for chest X-rays  
with multi-part textual answers, detailed bounding boxes, and structured tags**

# Our QBA Dataset

A large-scale VQA dataset for chest X-rays  
with multi-part textual answers, detailed bounding boxes, and structured tags

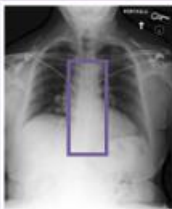## Study-level Questions

Describe abnormalities  
in the image

**Q: Describe all abnormal findings in the given study.**

The aorta appears somewhat tortuous.

POSITIVE CERTAIN



Categories:  
ANATOMICAL FINDING DISEASE

Subcategories:  
CARDIAC STRUCTURES MEDIASTINUM  
CARDIOVASCULAR DISEASES

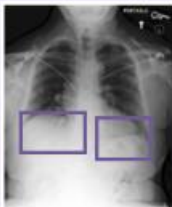Findings:  
tortuous aorta

Modifiers:  
severity: mkt texture: tortuous

Regions:  
aorta

There is bibasilar atelectasis.

POSITIVE CERTAIN BILATERAL



Categories:  
ANATOMICAL FINDING

Subcategories:  
LUNG FIELD

Findings:  
atelectasis

Modifiers:  
severity: mkt

Regions:  
lung base

# Our QBA Dataset

A large-scale VQA dataset for chest X-rays  
with multi-part textual answers, detailed bounding boxes, and structured tags

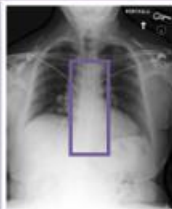
## Study-level Questions

Describe abnormalities  
in the image

**Q: Describe all abnormal findings in the given study.**

The aorta appears somewhat tortuous.

POSITIVE CERTAIN



Categories:  
ANATOMICAL FINDING DISEASE

Subcategories:  
CARDIAC STRUCTURES MEDIASTINUM  
CARDIOVASCULAR DISEASES

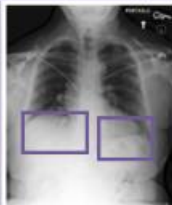Findings:  
tortuous aorta

Modifiers:  
severity: mkt texture: tortuous

Regions:  
aorta

There is bibasilar atelectasis.

POSITIVE CERTAIN BILATERAL



Categories:  
ANATOMICAL FINDING

Subcategories:  
LUNG FIELD

Findings:  
atelectasis

Modifiers:  
severity: mkt

Regions:  
lung base

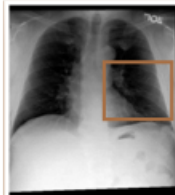## Region-level Questions

Describe anatomical regions or  
answer questions about them

**Q: Describe the ribs.**

A minimally displaced posterior left seventh rib fracture is noted.

POSITIVE CERTAIN LEFT



Categories:  
ANATOMICAL FINDING DISEASE

Subcategories:  
BONY STRUCTURES FRACTURE BONE

Findings:  
rib fracture

Modifiers:  
severity: small moderate

Regions:  
posterior 7th rib left

# Our QBA Dataset

A large-scale VQA dataset for chest X-rays  
with multi-part textual answers, detailed bounding boxes, and structured tags

## Study-level Questions

Describe abnormalities  
in the image

**Q: Describe all abnormal findings in the given study.**

The aorta appears somewhat tortuous.

POSITIVE CERTAIN



Categories:  
ANATOMICAL FINDING DISEASE

Subcategories:  
CARDIAC STRUCTURES MEDIASTINUM  
CARDIOVASCULAR DISEASES

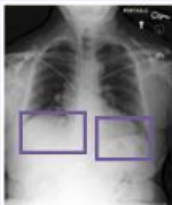Findings:  
tortuous aorta

Modifiers:  
severity: mkt texture: tortuous

Regions:  
aorta

There is bibasilar atelectasis.

POSITIVE CERTAIN BILATERAL



Categories:  
ANATOMICAL FINDING

Subcategories:  
LUNG FIELD

Findings:  
atelectasis

Modifiers:  
severity: mkt

Regions:  
lung base

## Region-level Questions

Describe anatomical regions or  
answer questions about them

**Q: Describe the ribs.**

A minimally displaced posterior left seventh rib fracture is noted.

POSITIVE CERTAIN LEFT



Categories:  
ANATOMICAL FINDING DISEASE

Subcategories:  
BONY STRUCTURES FRACTURE BONE

Findings:  
rib fracture

Modifiers:  
severity: small moderate

Regions:  
posterior 7th rib left

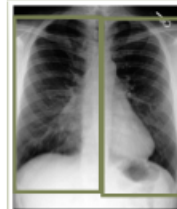
## Finding-level Questions

Answer questions about findings  
(e.g. presence, region, severity)

**Q: Is there any indication of consolidation?**

No, there is no indication of consolidation.

NEGATIVE CERTAIN BILATERAL



Categories:  
ANATOMICAL FINDING DISEASE

Subcategories:  
LUNG FIELD PULMONARY DISEASES

Findings:  
INFECTION  
consolidation

Regions:  
lungs

# Our QBA Dataset

A large-scale VQA dataset for chest X-rays  
with multi-part textual answers, detailed bounding boxes, and structured tags


## Study-level Questions

Describe abnormalities  
in the image

**Q: Describe all abnormal findings in the given study.**

The aorta appears somewhat tortuous.

POSITIVE CERTAIN




Categories: ANATOMICAL FINDING DISEASE  
Subcategories: CARDIAC STRUCTURES MEDIASTINUM CARDIOVASCULAR DISEASES  
Findings: tortuous aorta  
Modifiers: severity: mkt texture: tortuous  
Regions: aorta

---

There is bibasilar atelectasis.

POSITIVE CERTAIN BILATERAL



Categories: ANATOMICAL FINDING  
Subcategories: LUNG FIELD  
Findings: atelectasis  
Modifiers: severity: mkt  
Regions: lung base


## Region-level Questions

Describe anatomical regions or  
answer questions about them

**Q: Describe the ribs.**

A minimally displaced posterior left seventh rib fracture is noted.

POSITIVE CERTAIN LEFT



Categories: ANATOMICAL FINDING DISEASE  
Subcategories: BONY STRUCTURES FRACTURE BONE  
Findings: rib fracture  
Modifiers: severity: small moderate  
Regions: posterior 7th rib left


## Finding-level Questions

Answer questions about findings  
(e.g. presence, region, severity)

**Q: Is there any indication of consolidation?**

No, there is no indication of consolidation.

NEGATIVE CERTAIN BILATERAL



Categories: ANATOMICAL FINDING DISEASE  
Subcategories: LUNG FIELD PULMONARY DISEASES  
Findings: INFECTION consolidation  
Regions: lungs


## Indication Questions

Describe the image  
w.r.t. the given indication.

**Q: Male with severe disease, possible pneumonia, and continued aspiration; should be evaluated for pneumonia.**

Pneumonia is presumed due to the extensive right infrahilar consolidation, although some of this could be due to atelectasis.

POSITIVE UNCERTAIN RIGHT

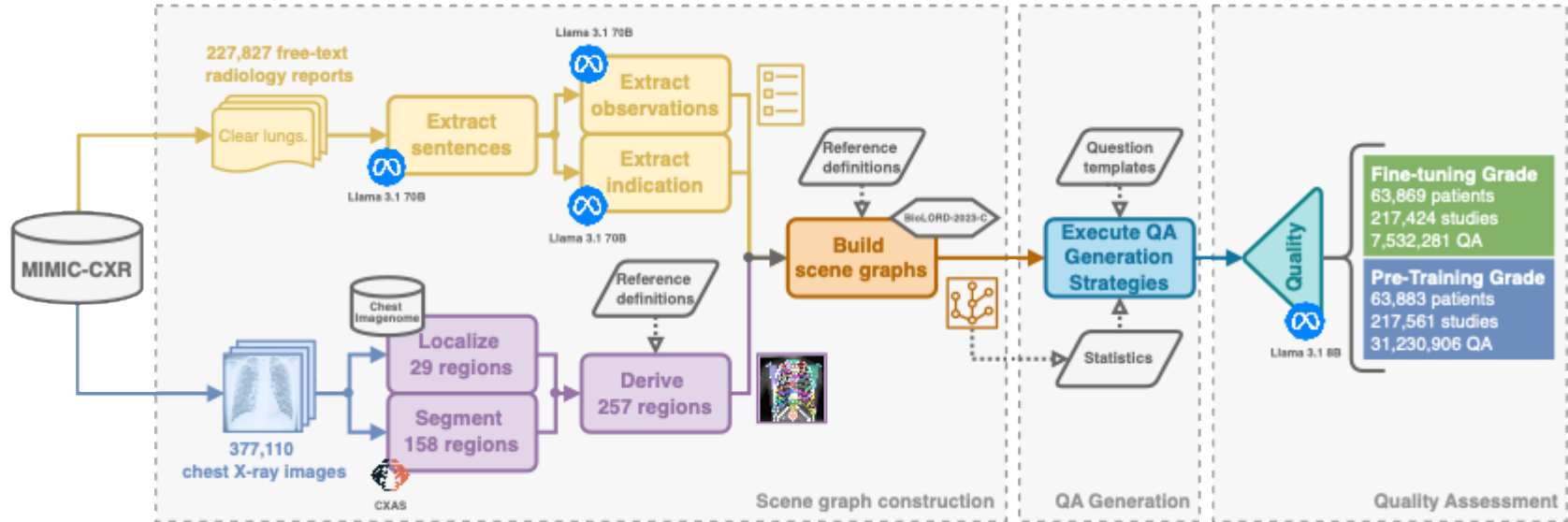


Categories: ANATOMICAL FINDING DISEASE  
Subcategories: INFECTION LUNG FIELD PULMONARY DISEASES  
Findings: atelectasis consolidation pneumonia  
Modifiers: spread: focal  
Regions: right infrahilar region

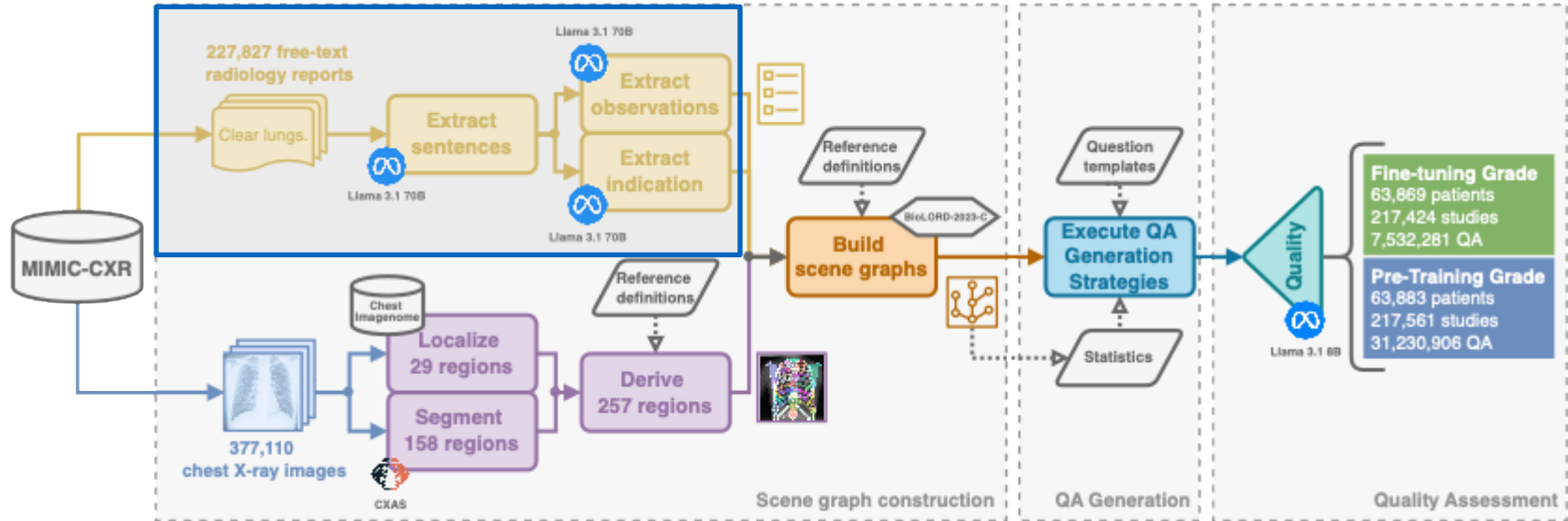
# Our QBA Dataset

- **42M** question-answer (QA) pairs  
(7.5 M Fine-tuning Grade)
- **230k** studies (from MIMIC-CXR)
- **180k** unique questions
- **7.8M** unique answer texts
- Median answer length of **40 words**
- **27** question types
- **257** region tags
- **221** finding tags

# Dataset Construction Pipeline



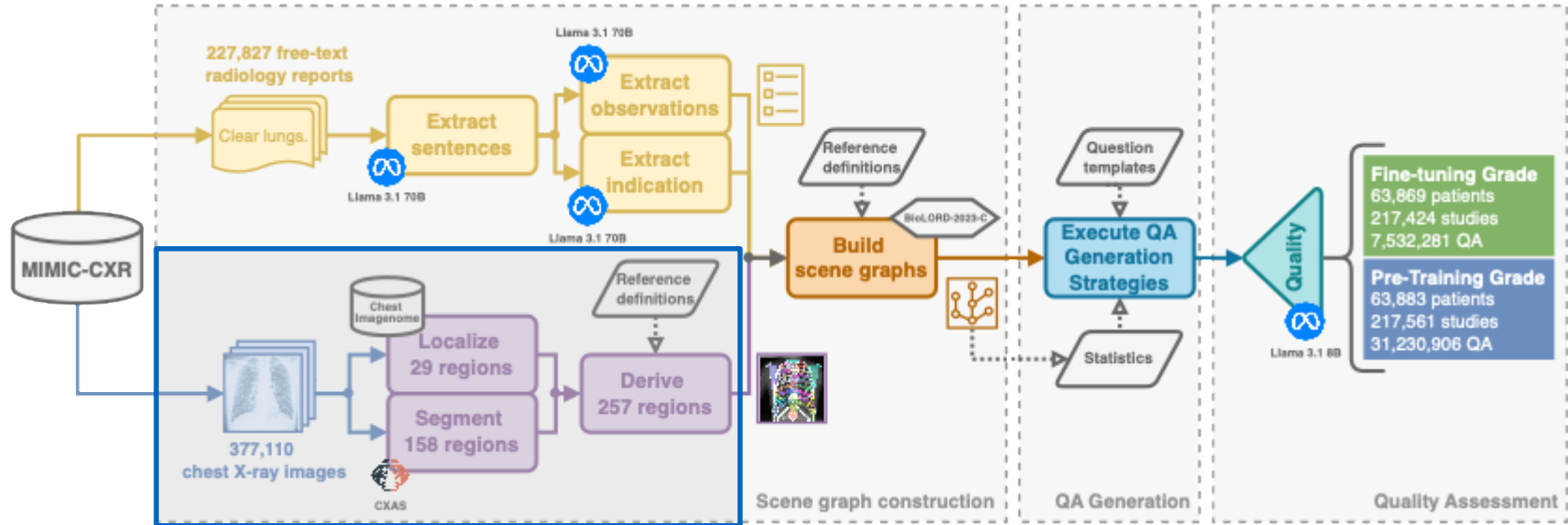
# Dataset Construction Pipeline



## 1. Extract sentences, indications, and observations

Convert radiology reports into structured jsons using multi-step LLM-based information extraction

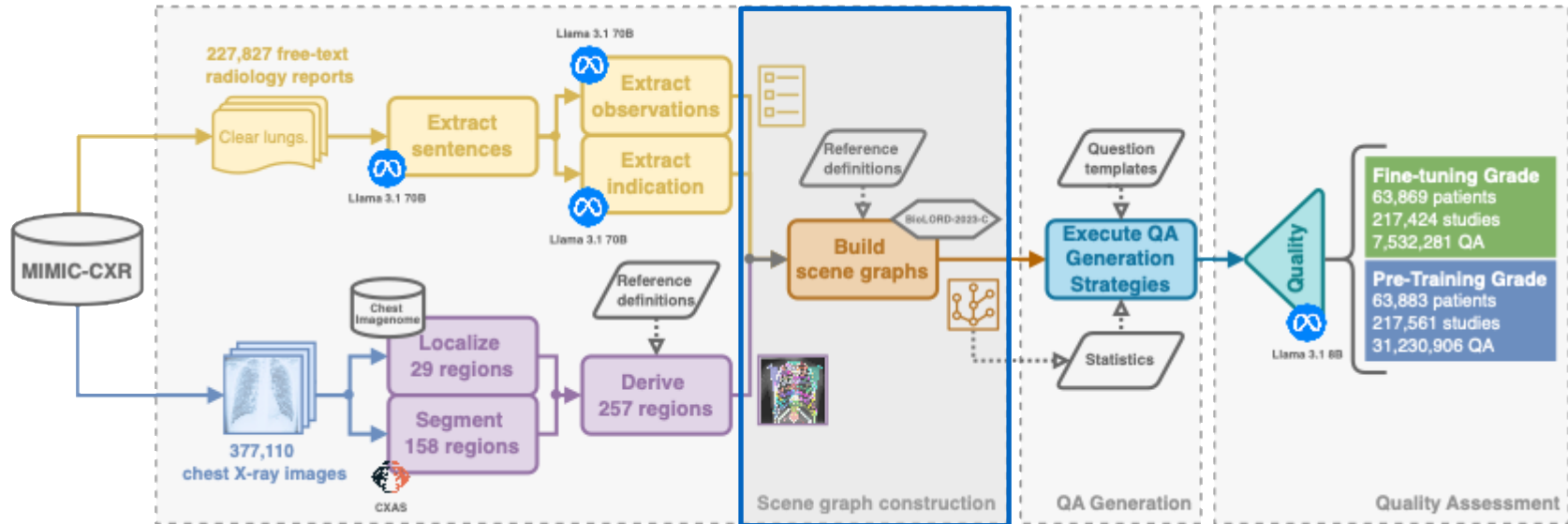
# Dataset Construction Pipeline



## 2. Localize anatomical regions

Using Chest Imagenome bounding boxes and CXAS segmentation model

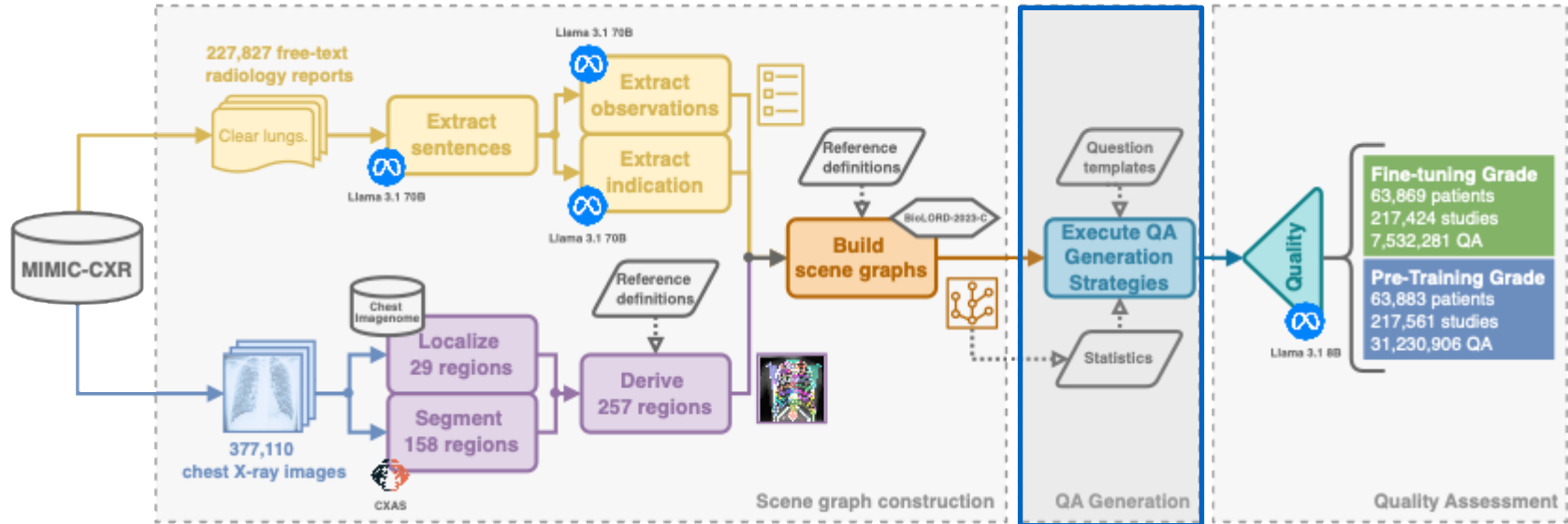
# Dataset Construction Pipeline



## 3. Build scene graphs

Map extracted information to reference definitions (using BioLORD entity mapping) and combine it with region bounding boxes to final scene graphs

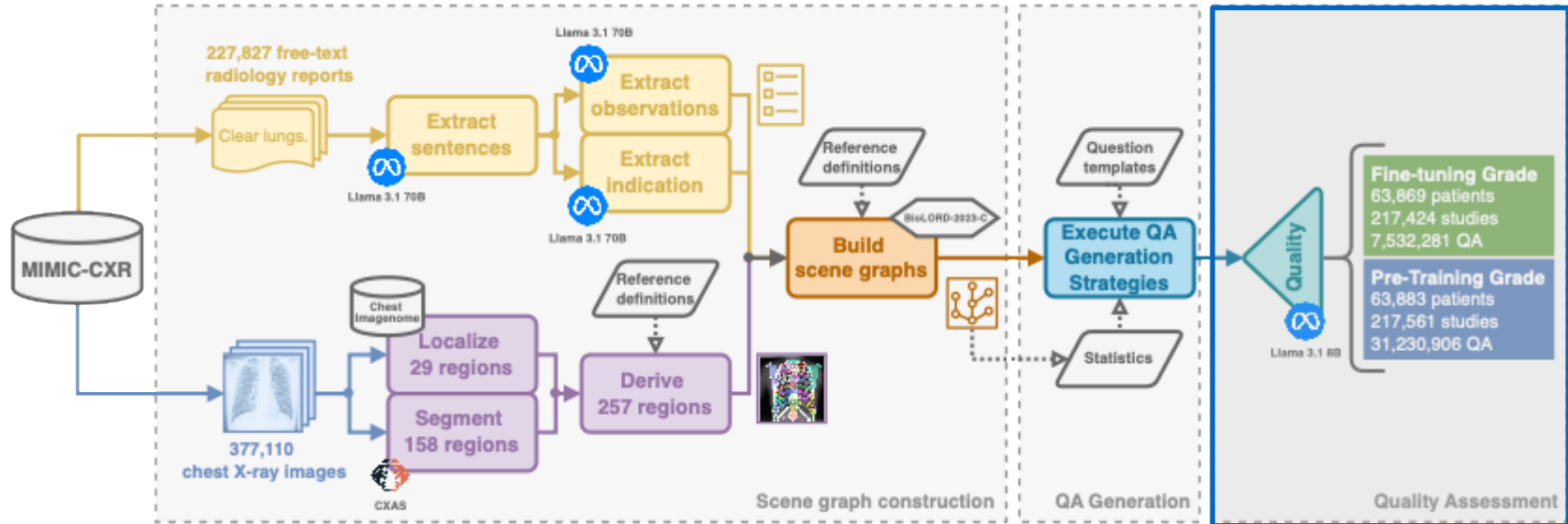
# Dataset Construction Pipeline



## 4. Generate Question-Answer Pairs from Scene Graphs

Use predefined question templates and scene graphs to construct QA pairs. Answers are based on the extracted sentences from the reports.

# Dataset Construction Pipeline



## 5. Automatic Quality Assessment and Grading

Using LLM-Judge


# Evaluation

- Export-annotated **bounding boxes** of finding subsets
- Expert-annotated **tags** of finding subsets
- **LLM-judge** for questions and answers (5 criteria) validated against **human annotator**

# Potential Applications

- Structured, grounded, and localized **visual question answering (VQA)**
- Structured and grounded radiology **report generation**
- Fine-grained finding and pathology **classification and localization**
- **Scene graph** generation
- **VLM** pretraining

## How to Use



<https://physionet.org/content/mimic-ext-cxr-qba/1.0.0/>

Download Dataset

PhysioNet 

<https://github.com/philip-mueller/mimic-ext-cxr-qba>

Utilities and Sourcecode

